



PATIENT

CJ Buzzard

SPECIES

Canine

BREED

Chihuahua

SEX

Female Spayed

AGE

15 years

WEIGHT

8lbs

INTERPRETED BY

Maggie Machen Lamy,
DVM DACVIM
(Cardiology)

IMAGING PERFORMED BY

Kelly Reschny, RVT

HOSPITAL NAME

Hamilton Region
Veterinary Emergency
Clinic

REFERRING VET

Dr. Ho

INVOICE

47691

DATE

4/27/26

PRESENTING CLINICAL SIGNS

History: Presented for suspect choking, syncopal episode, struggled to get up, lost control of bowels, making strange sounds, appearing to gasp for air, no known trigger. PE: severe dental disease, grade 5/6 LEFT systolic apical heart murmur. SpO2 98% on room air. Abdominal pain. ECG showed suspect 3rd degree AV block. Hypertensive on presentation (systolic consistently 160-170mmHg), TFAST & AFAST: no clinically significant findings. Patient fractious. On Butorphanol and Propofol
Abnormal PE/Chem/CBC/UA Results: Moderate hemoconcentration (hct 69), mild lymphopenia (0.89), mild hyperglycemia (BG 12.4), mild azotemia (Cr 199, BUN 15.5), mild hypophosphatemia (P 0.72), mildly elevated ALT (161), elevated pancreatic lipase (340), urine from cystocentesis sample, USG 1022, mild hematuria, quiet sediment

ELECTROCARDIOGRAPHIC FINDINGS

A six lead ECG is available at 25mm/s; 10mm/mV. The average heart rate is 140bpm. The rhythm is sinus in origin, with a p for every QRS complex and vice versa. The P wave morphology is positive with a normal dimension. Normal PR. The QRS morphology is positive with normal dimension. MEA is normal. No ectopic beats, pauses or dysrhythmias observed.
ECG diagnosis: Normal sinus rhythm with respiratory variation.

ECHOCARDIOGRAM FINDINGS

2D, m-mode, color flow and doppler imaging is available. Diffuse thickening of mitral valve leaflets with prolapse into the left atrial lumen. Moderate eccentric mitral regurgitation with mild left atrial dilation. Normal MR velocity. Normal LV diameter with adequate myocardial function. The tricuspid valve appears normal with no tricuspid regurgitation. Normal right atrial and ventricular diameter and morphology indicating no overt evidence of pulmonary arterial hypertension. The pulmonic and aortic valves are normal in morphology and mobility. Normal pulmonic and aortic outflow velocities with laminar flow. No obvious aortic or pulmonic insufficiency. No pericardial or pleural effusion noted. No obvious cardiac masses.

CARDIAC CHART

CANINE CARDIAC PARAMETERS	MR VMAX (m/s)	TR VMAX (m/s)	LA/AO (Boon method)	LA/AO (Heart Base; Swe)	FS (%)	EF (%)	EPSS (cm)
NORMAL PARAMETER	4.5-5.5	<2.7	1.3	<1.6	28-40	40-100	<0.6
PATIENT	6.5		1.1	1.5	45	86	NM
CANINE CARDIAC PARAMETERS	HR (BPM)	AV VMAX (m/s)	PV MAX (m/s)	BODY WEIGHT (kg)	LA 2D short axis Base view (cm)	LVIDd Avg; 2D and m-mode short axis (cm)	LVIDs Avg; 2D and m-mode short axis (cm)
NORMAL PARAMETER	50-100	0.7-1.7	0.7-1.6	BELOW	BELOW	BELOW	BELOW
PATIENT	100	0.9	0.7	4.4	1.7	2.5	1.2
*Normal chamber parameters expressed as a mean value (SD)				3	1.27 (5.3)	2.46 (2.46)	1.36 (5.5)
BODY WEIGHT DEPENDENT PARAMETERS				5	1.40 (4.5)	2.74 (5.2)	1.60 (4.7)
				10	1.50 (3.8)	3.27 (3.5)	2.06 (3.1)
				15	1.83 (2.0)	3.71 (2.4)	2.43 (2.1)



PATIENT

CJ Buzzard

SPECIES

Canine

BREED

Chihuahua

SEX

Female Spayed

AGE

15 years

WEIGHT

8lbs

INTERPRETED BY

Maggie Machen Lamy,
 DVM DACVIM
 (Cardiology)

IMAGING PERFORMED BY

Kelly Reschny, RVT

HOSPITAL NAME

Hamilton Region
 Veterinary Emergency
 Clinic

REFERRING VET

Dr. Ho

INVOICE

47691

DATE

4/27/26

**Note: All measurements based upon multi-modal images and methods. An average value is reported.*

Adapted from June Boon, Veterinary Echocardiography, 1998
 Rishniw M and Hollis NE, J Vet Intern Med 2000; 14:429-435
 Hansson et al, Vet Rad and Ultrasound 2002

20	2.02 (1.9)	4.14 (2.2)	2.80 (2.0)
25	2.18 (2.4)	4.48 (2.9)	3.10 (2.5)
30	2.33 (3.3)	4.83 (3.9)	3.39 (3.4)
35	2.48 (4.3)	5.17 (5.0)	3.69 (4.5)
40	2.62 (5.2)	5.48 (6.1)	3.96 (5.4)
50	2.88 (7.1)	6.07 (8.3)	4.46 (7.4)

INTERPRETATION OF THE FINDINGS & FURTHER RECOMMENDATIONS

Chronic degenerative valve disease causing moderate mitral regurgitation. Lack of significant left atrial enlargement indicates the current risk for complication is low. No concurrent issues such as systolic dysfunction or pulmonary hypertension are noted in this study. The ECG is unremarkable with a normal sinus rhythm. No AV block is appreciated.

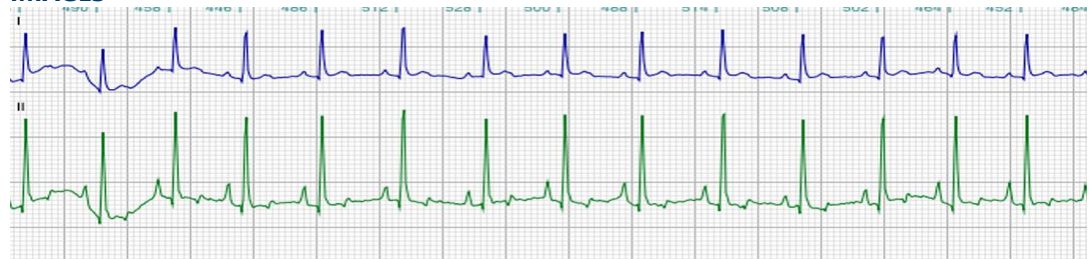These findings do not clearly explain the reported clinical episode. Full work up is advised, including CXR as the next step to assess for causes (PTE, respiratory crisis, etc). A ruptured chord is theoretically possible as these are not always visible on 2D ultrasound; however, this is of less concern given a low resting heart rate.

In a dog with no significant left atrial enlargement, no cardiac medications are clearly indicated. Assessment of progression in the future will help predict long term prognosis, which is highly variable at this stage. Omega fatty acid supplementation and mild salt restriction may be of some long-term benefit. Monitor for development of a cough, labored breathing, exercise intolerance or collapse episodes.

Anesthetic risk is considered mild if needed. Cardiac protective drug choices (opioid/benzodiazepine premedication, propofol or alfaxalone induction, isoflurane gas) are recommended. Pre-oxygenate for 5-10 minutes prior to induction. Monitor for arrhythmias, hypotension, and hypoxia both intra and post-operatively and intervene as necessary. Mild IV fluid restriction is recommended to avoid fluid overload. Avoid heart rate stimulating drugs such as atropine unless clinically indicated.

Recommend conservative monitoring with a recheck echocardiogram in 6 months, sooner if any development of clinical signs.

IMAGES





PATIENT

CJ Buzzard

SPECIES

Canine

BREED

Chihuahua

SEX

Female Spayed

AGE

15 years

WEIGHT

8lbs

INTERPRETED BY

Maggie Machen Lamy,
DVM DACVIM
(Cardiology)

IMAGING PERFORMED BY

Kelly Reschny, RVT

HOSPITAL NAME

Hamilton Region
Veterinary Emergency
Clinic

REFERRING VET

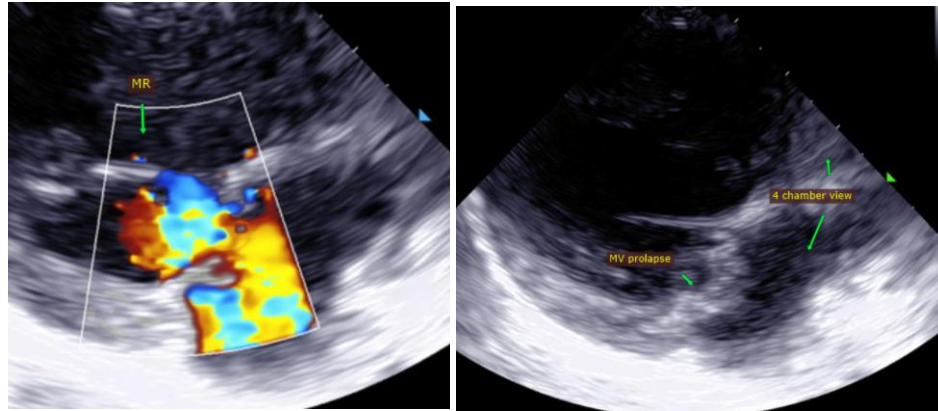
Dr. Ho

INVOICE

47691

DATE

4/27/26



The information and recommendations provided are based on the images presented by the referring veterinarian. No evaluation can be communicated regarding pathology that was not visible in the image/video clips provided.

Thank you for this referral. This report was generated using transcription software, and minor dictation errors may be present. If the clinical or image interpretation does not parallel your findings or if I can be of any further assistance, please contact me.

Maggie Machen Lamy, DVM
Diplomate of the American College of Veterinary Internal Medicine (Cardiology)
info@sonopath.com